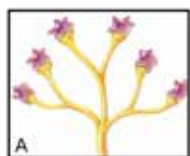
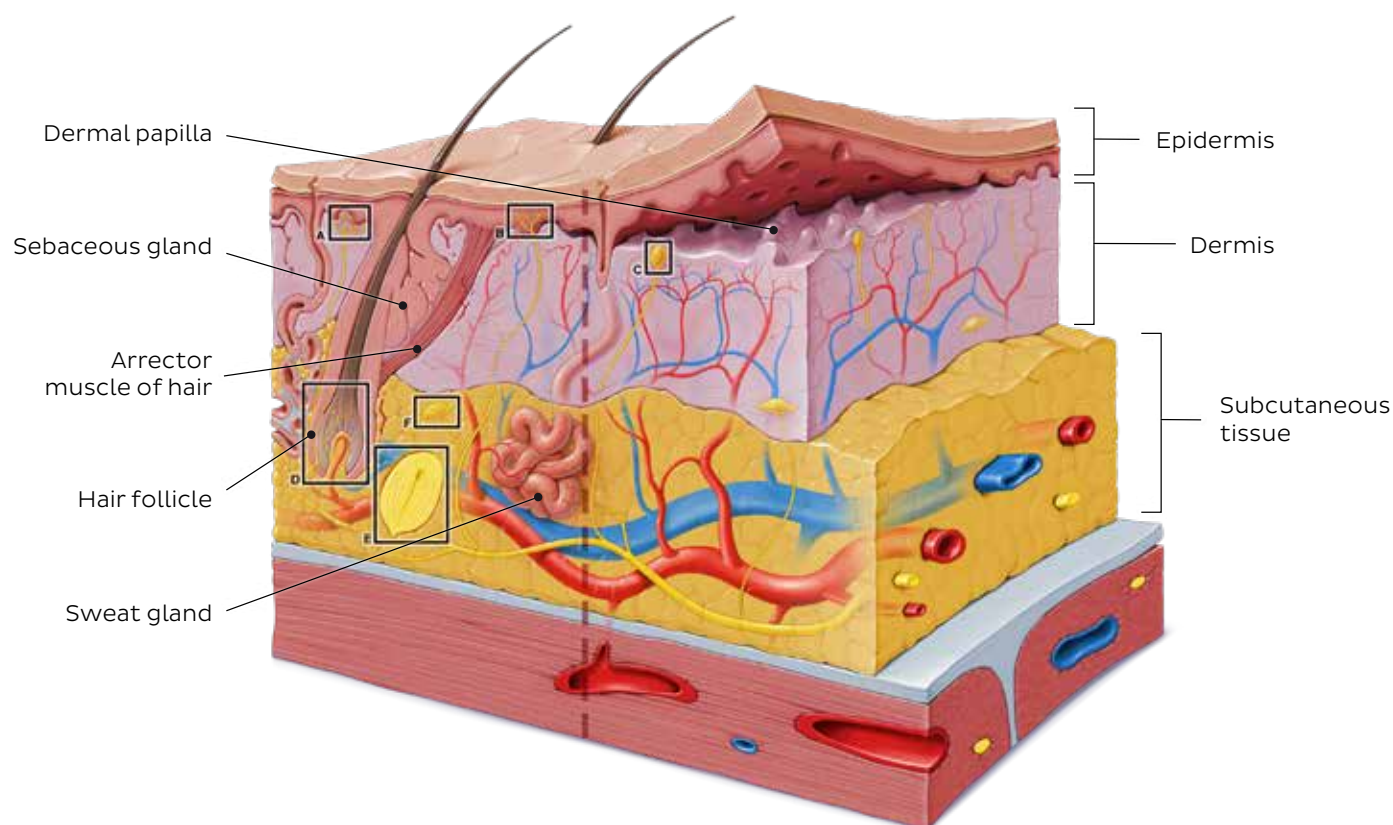
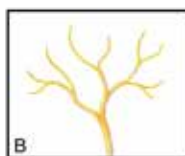


Worksheet

Integumentary system



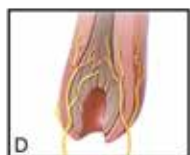A
Epithelial tactile complex



B
Free nerve ending



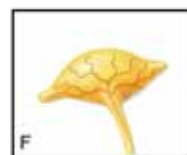
C
Tactile corpuscle



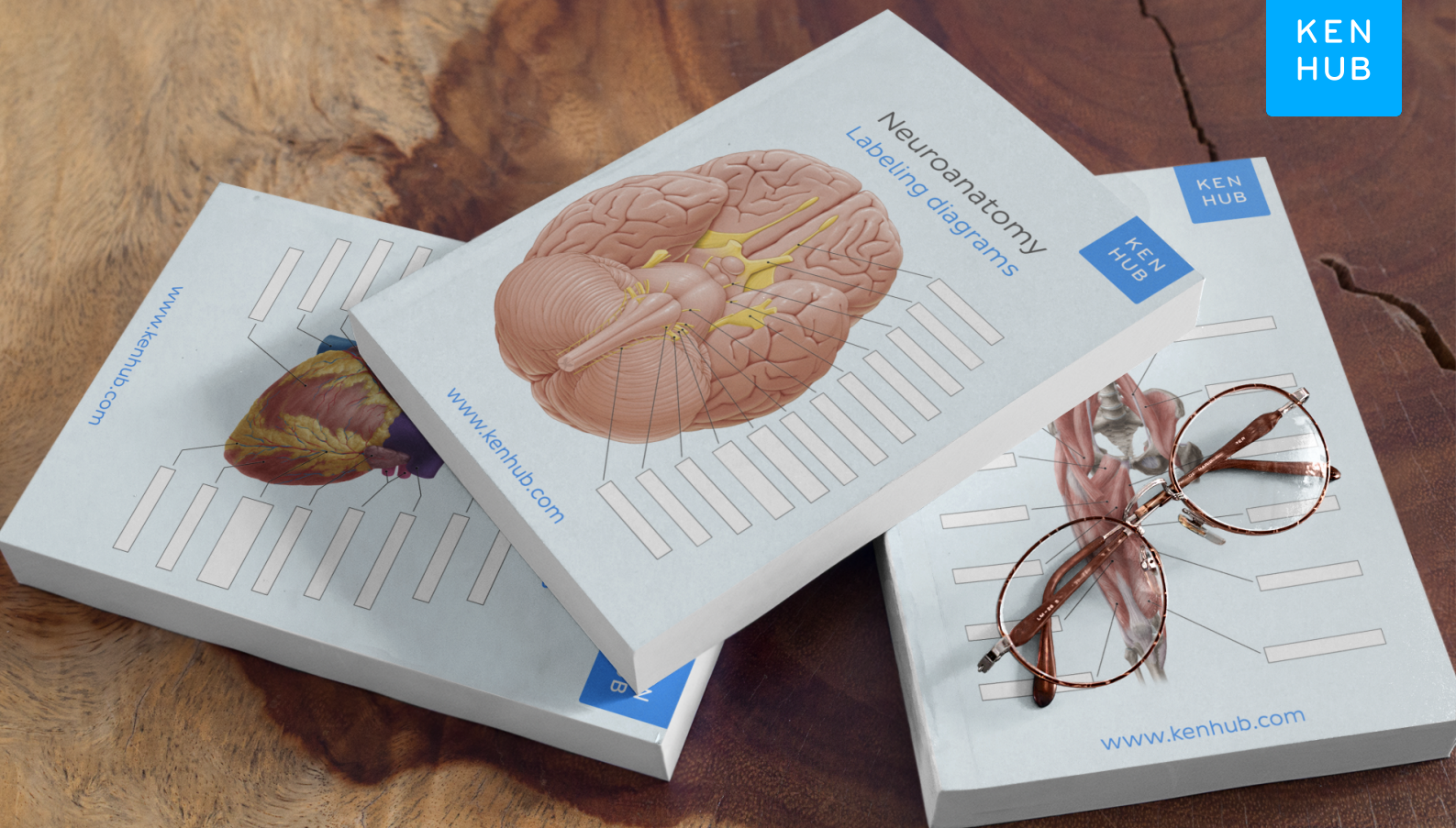
D
Hair follicle ending



E
Lamellar corpuscle



F
Bulbous corpuscle

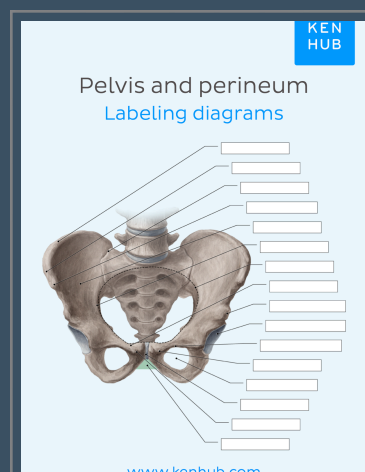
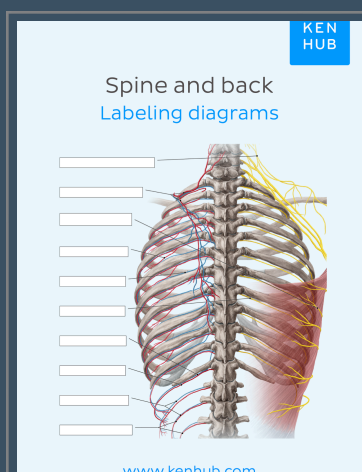
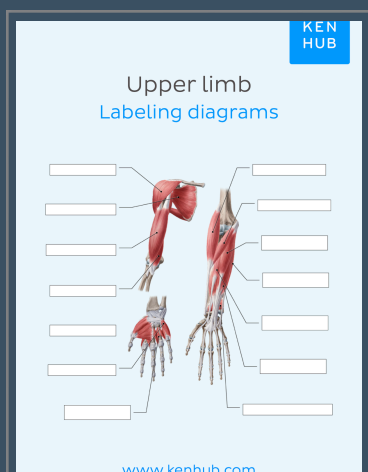


Complete your labeling diagrams collection

Congratulations – you’ve started to conquer the most important anatomical terminology! But there’s still a lot of structures to learn, so don’t stop here.

Get your Kenhub labeling diagrams for every region of the the body.

Click below to learn more.



[LEARN MORE](#)