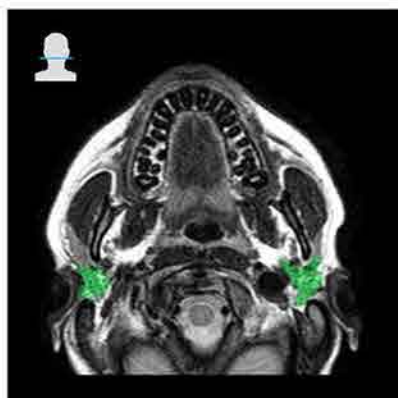
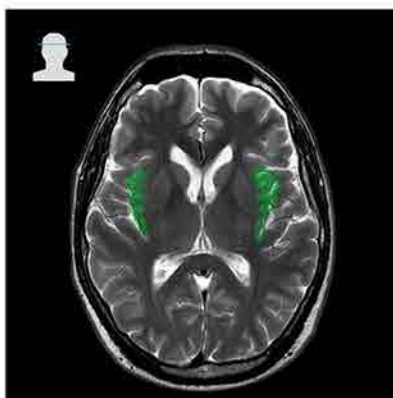


Apostila

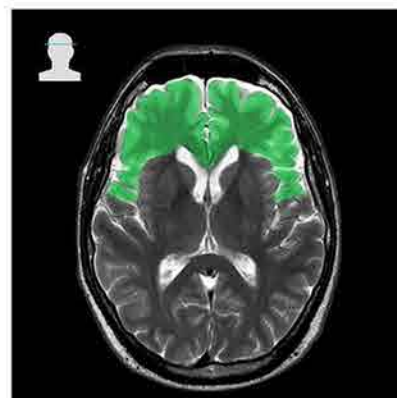
Identificação de Estruturas



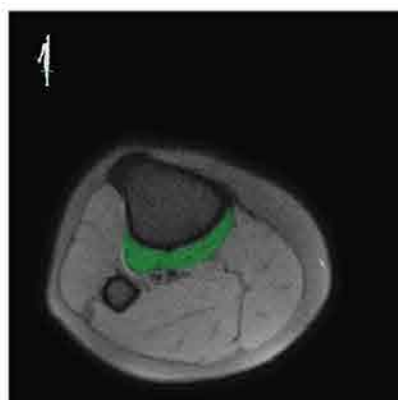
Glândula
parótida



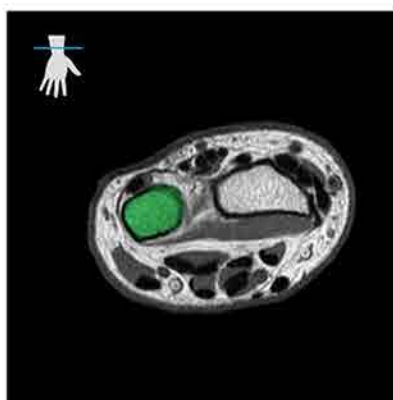
Lobo insular



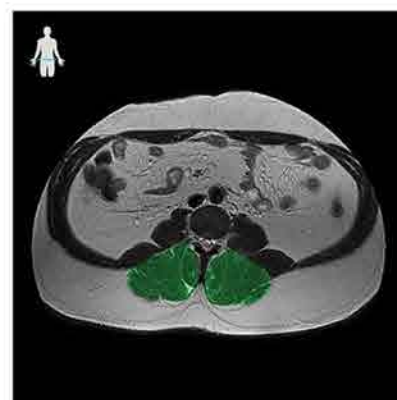Lobo frontal



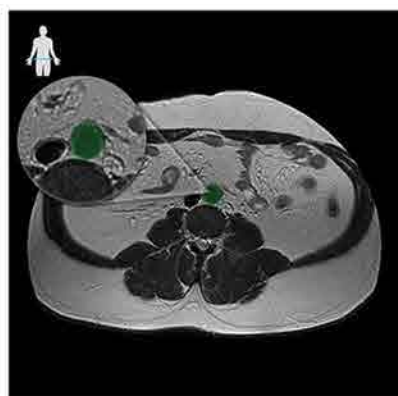
Músculo
poplíteo



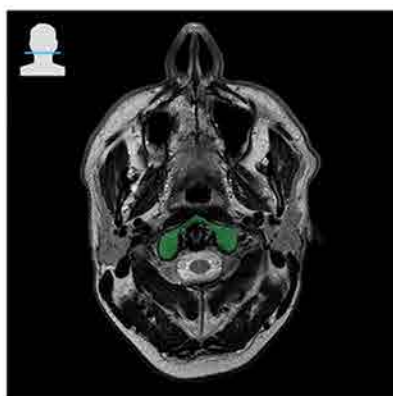
Ulna



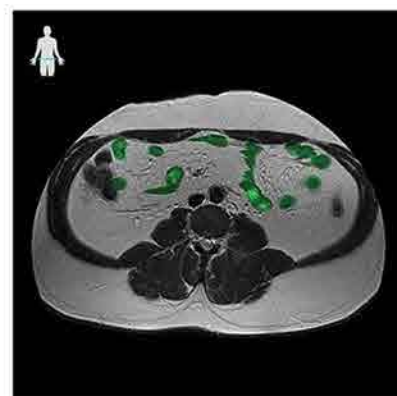Eretores da
espinha



Aorta
abdominal



Atlas



Intestino
delgado